

VACUMED CASE REPORT

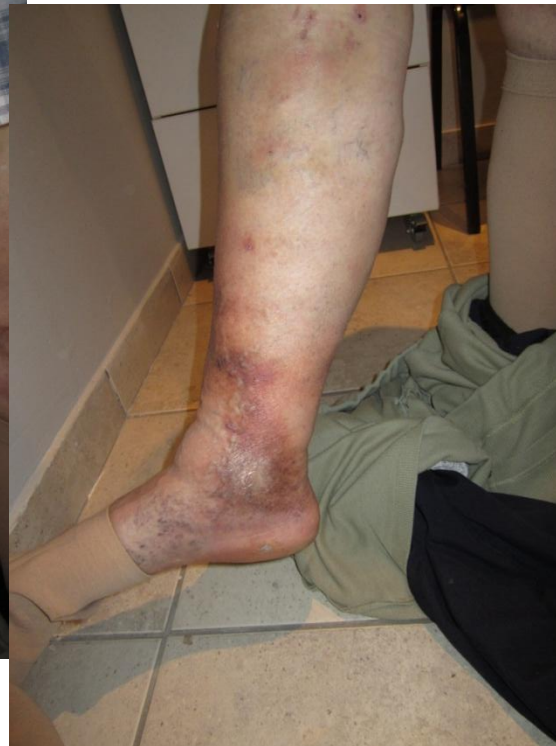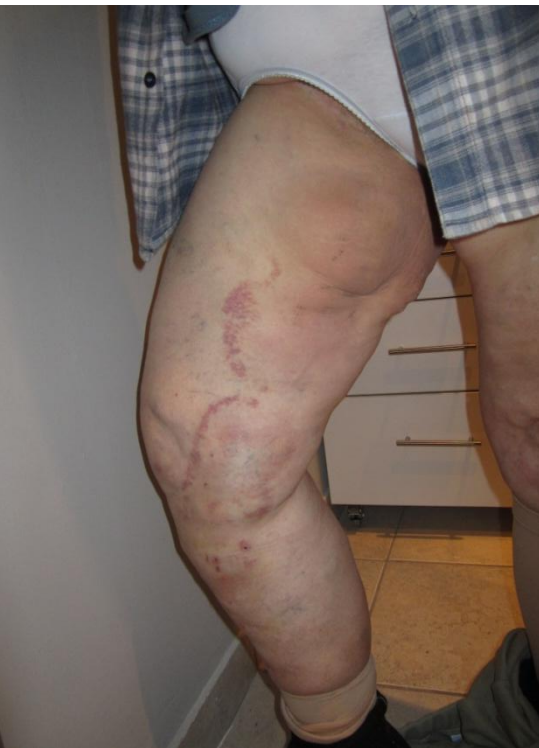Sr. Liezl Naude (*BCur, MCur, IIWCC*)



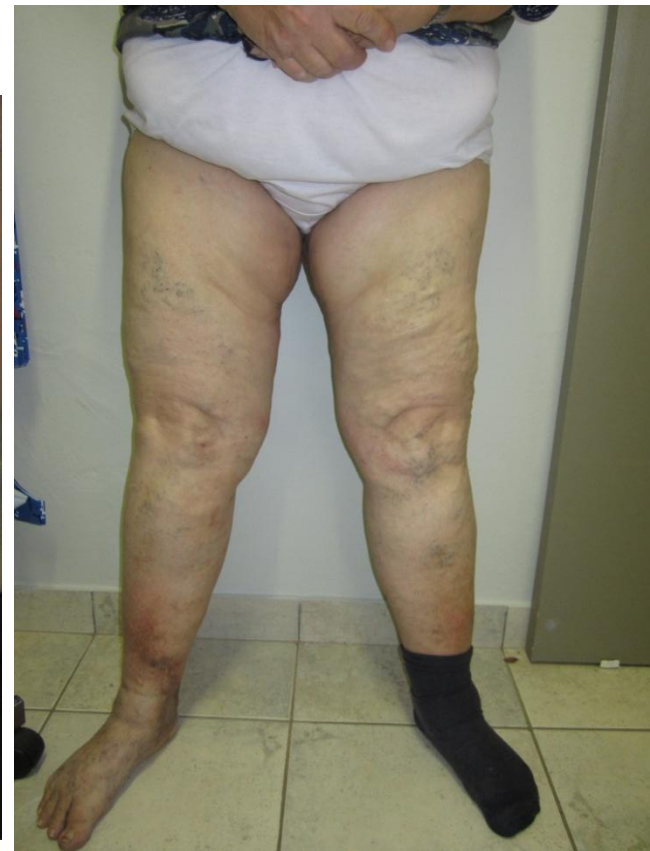ADVANCED LOWER LIMB
— & —
WOUND MANAGEMENT
CENTRE

Patient post op Vein stripping (P8 - 40 min)

Session 1 - anterior

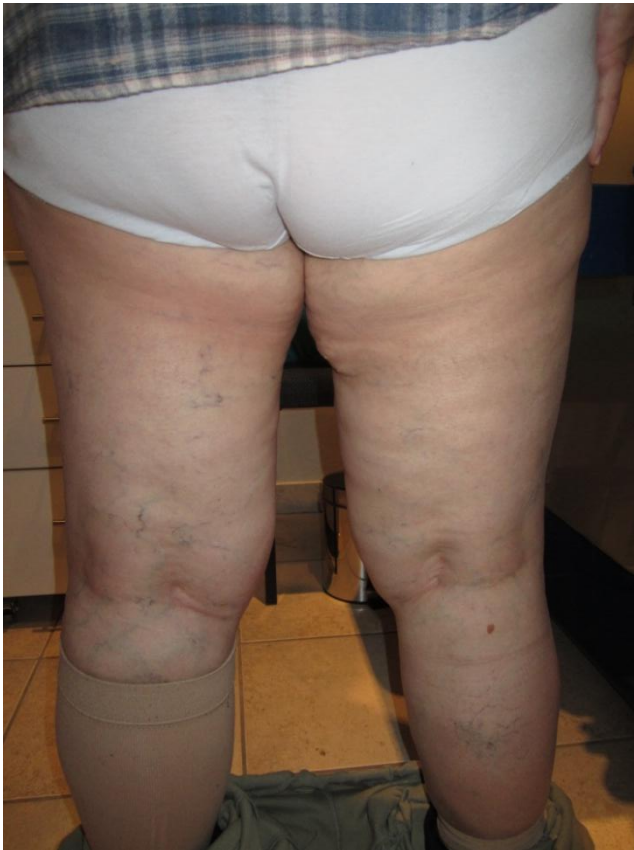

Session 8 - anterior

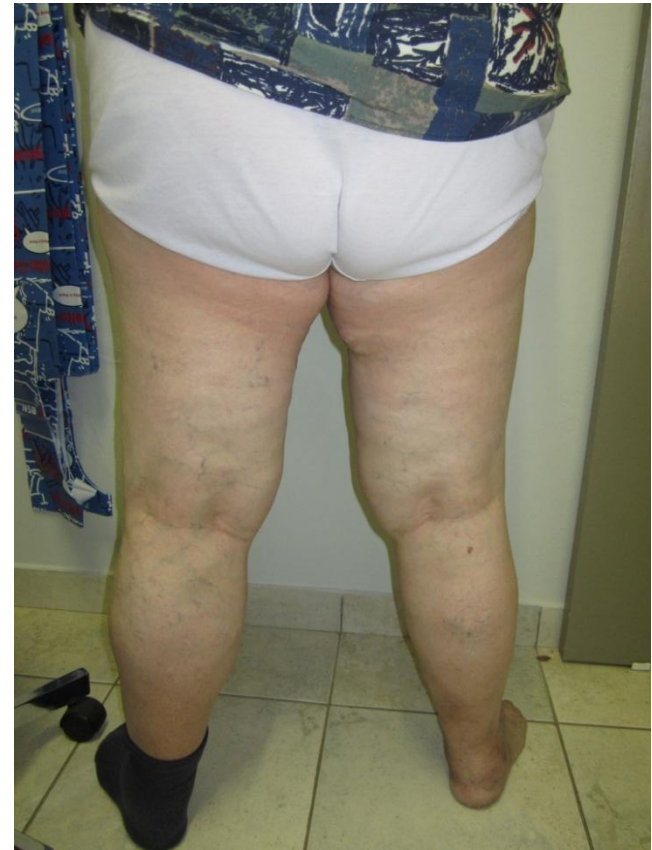

Patient post op Vein stripping (P8 - 40 min)

Session 1 - posterior

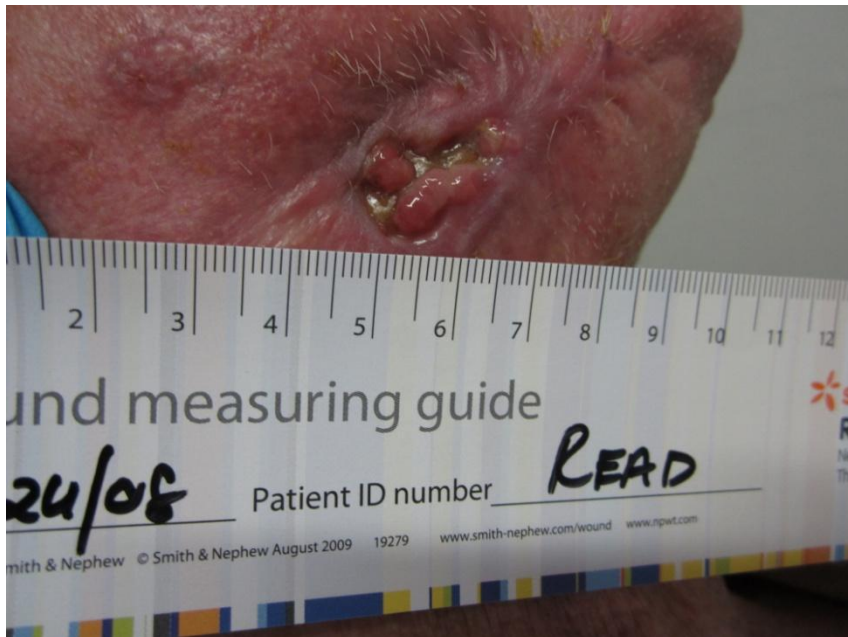


Session 8 - posterior

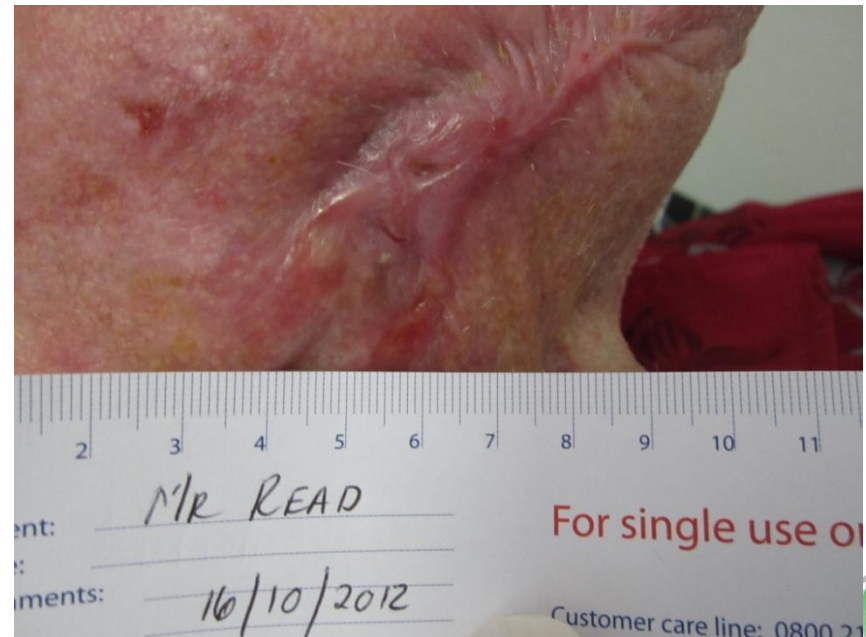

Patient with exposed bone and compromised blood flow. Only able to do 1-2 sessions per week. (P8 - 40 min)

Session 1 – exposed bone with hyper-granulation tissue

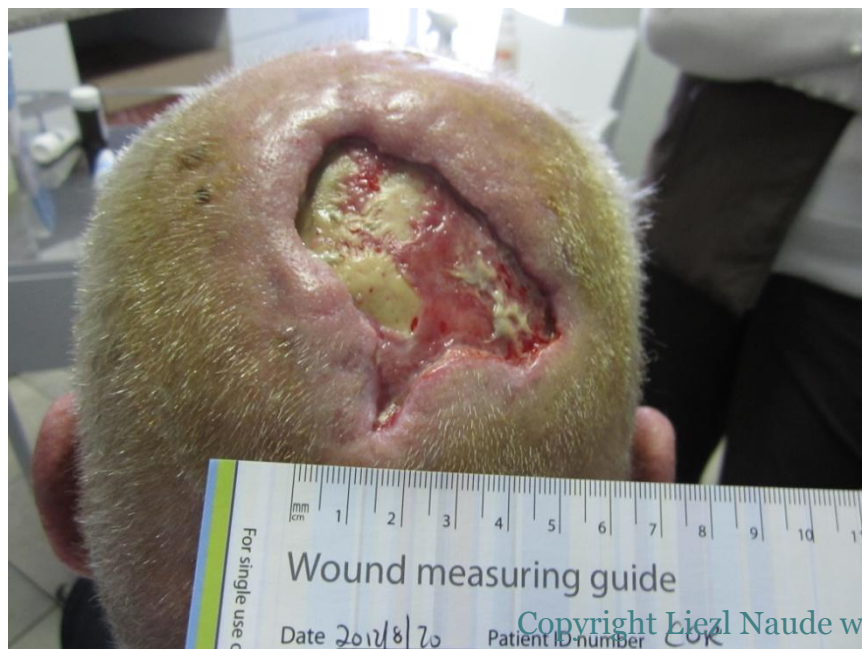

Session 10 – exposed bone with hyper-granulation tissue

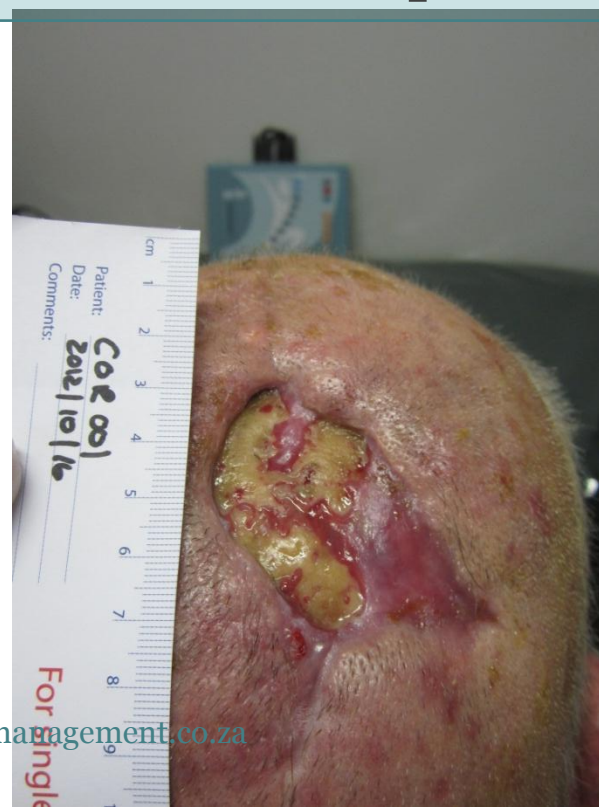

Patient with exposed bone Saturation rate at onset of treatment 72%. Pt did 2-3 sessions per week resulting in Saturation of 90%. (P8 - 40 min)

Session 1 – Exposed bone post basal cell carcinoma excision and subsequent flap failure

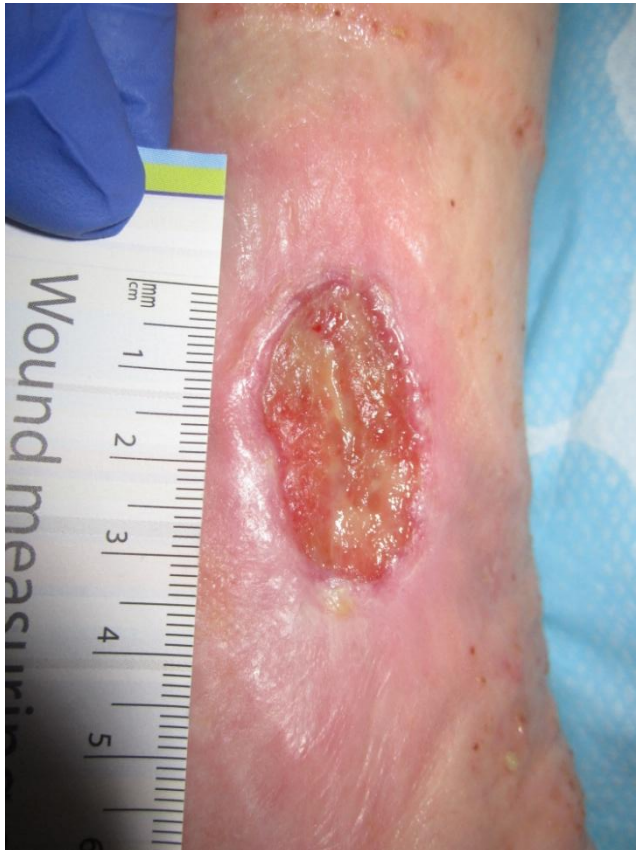

Session 18 – Healthy epithelial tissue with new granulation tissue visible on exposed bone

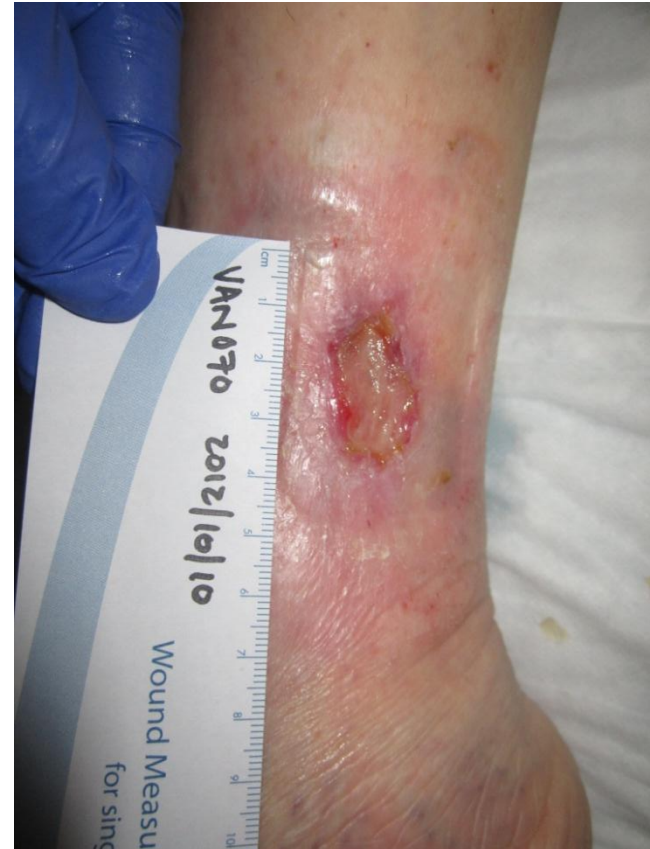

Patient with chronic venous ulceration > 2 years, patient travels 300km to centre weekly (P8 - 40 min)

Session 1 – once a week



Session 4 – significant pain decrease and no oedema



Copyright Liezl Naude www.woundmanagement.co.za



ADVANCED LOWER LIMB
&
WOUND MANAGEMENT
CENTRE